International Journal of Engineering and Advanced Technology (IJEAT)
ISSN: 2249-8958 (Online), Volume-2 Issue-3, February 2013

A Review of Thyroid Disorder Detection, Segmentation and Classification on Medical Images

Sheeja Agustin A, S. Suresh Babu

Abstract- Thyroid is a small butterfly shaped gland located in the front of the neck just below the Adams apple. Thyroid is one of the endocrine gland, which produces hormones that help the body to control metabolism. Different thyroid disorders include Hyperthyroidism, Hypothyroidism, goiter, and thyroid nodules (benign/malignant). Ultrasound imaging is most commonly used to detect and classify abnormalities of the thyroid gland. Other modalities (CT/MRI) are also used. Computer aided diagnosis (CAD) help radiologists and doctors to increase the diagnosis accuracy, reduce biopsy ratio and save their time and effort. Numerous researches have been carried out in thyroid medical images and that are utilized for the diagnosis process. In this paper, a broad review on the researches that are developed for the thyroid diagnosis using medical images is presented along with the classification. A short description about thyroid, thyroid diseases and thyroid diagnosis are also presented.

Key terms:-Medical imaging, Thyroid, Thyroid disorders, Segmentation, Classification.

I. INTRODUCTION

Image processing is any form of signal processing for which the input is an image such as photograph or video frame, the output of image processing may be either an image or parameters related to the image. Image processing usually refers to digital image processing. Digital image processing is the use of computer algorithms to perform image processing on digital images. Different Imaging technologies are:-Radiology, Magnetic resonance imaging (MRI), Nuclear medicine, Photo acoustic imaging, Breast thermograph, Tomography and ultrasound imaging. Medical imaging is the technique and process used to create images of the human body for clinical purpose or medical science including the study of normal anatomy and physiology.

Image segmentation is the process of partitioning an image into multiple segment or set of pixels used to locate object and boundaries. Each of the pixels in a region is similar with respect to some characteristics such as color, intensity or texture. One of the common applications of segmentation is in medical image analysis for clinical diagnosis that has an important role in terms of quality and quantity. Medical image segmentation methods generally have restrictions because medical images have very similar gray level and texture among the interested objects. Therefore, significant segmentation error may occur.

Manuscript published on 30 February 2013.
***** Correspondence Author (s)
Sheeja Agustin*, Research Scholar, Computer science & Engineering, Noorul Islam Centre for Higher Education, Noorul Islam University, Kumaracoil,TamilNadu, India.
Dr.S.Suresh Babu, Electronics & Communication Engineering, Professor, TKM College of Engineering, Kollam, India.

Another difficulty may arise due to the lack of sufficient training samples. In the field of Image analysis segmentation of medical images is a challenging problem due to poor resolution and weak contrast of medical images. Medical image segmentation means Segmentation of known anatomic structures from medical images. Now a day's Medical image analysis has played more and more important role in many clinical procedures and in detecting different types of human diseases. Now a day's most of the peoples have thyroid diseases.

For diagnosing thyroid diseases, Ultrasound (US) and Computerized Tomography (CT) are two of the most popular imaging modalities. US imaging is inexpensive, non-invasive and easy to use. US images are often adopted due to their cost-effectiveness and portability in smaller hospitals. The thyroid is well suited to ultrasound study because of its superficial location, size and echogenicity .Computer-Aided Diagnosis (CAD) of Thyroid Ultrasound is necessary in order to delineating nodules, classifying benign/malignant and estimating the volumes of thyroid tissues to increase reliability and reduce invasive operations such as biopsy and Fine Needle Aspiration (FNA).

Fig1: Normal Thyroid US image

In digital image classification the conventional statistical approaches for image classification use only the gray values. Different advanced techniques in image classification like Artificial Neural Networks (ANN), Support Vector Machines (SVM), Fuzzy measures, Genetic Algorithms (GA), Fuzzy support Vector Machines (FSVM) and Genetic Algorithms with Neural Networks are being developed for image classification. The use of textural features in ANN helps to resolve misclassification. SVM was found competitive with the best available machine learning algorithms in classifying high-dimensional data sets. ANN is a parallel distributed processor that has a natural tendency for storing experiential knowledge. Image classification using neural networks is done by texture feature extraction and then applying the back propagation algorithm.

Published By:
Blue Eyes Intelligence Engineering and Sciences Publication (BEIESP)

The rest of this paper is organized as follows. In Section II describes about different disorders and symptoms, section III describes review on thyroid disorders, section IV describes about Reviewed results. Finally, the conclusions as well as future directions are summarized in Section V.

II. DIFFERENT DISORDERS IN THYROID

A. *Thyroid Diseases*

Thyroid gland produces chemicals (hormones) that help the body to control metabolism. Thyroid hormone is normally produced in response to another hormone released by the pituitary gland. There are four main types of thyroid disease [11]-hyperthyroidism (too much thyroid hormone), hypothyroidism (too little thyroid hormone), benign (noncancerous) thyroid disease and thyroid cancer(malignant).

B. *Thyroid Disease Symptoms*

The signs and symptoms of hypothyroidism includes fatigue, mental fogginess and forgetfulness, feeling excessively cold, constipation, dry skin, fluid retention, non specific aches and stiffness in muscles and joints, excessive or prolonged menstrual bleeding (menorrhagia), and depression. Hyperthyroidism is suggested by a number of signs and symptoms. People with mild hyperthyroidism or those older than 70 years of age usually experience no symptoms. Common symptoms of hyperthyroidism includes excessive sweating, heat intolerance, increased bowel movements, tremor (usually a fine shake), nervousness; agitation, rapid heart rate, weight loss, fatigue, decreased concentration, and irregular and scant menstrual flow.

The two most important thyroid hormones are thyroxine (T4) and triidothyronine(T3), representing 99.9% and 0.1% [14] of thyroid hormones respectively. The hormone with the most biological power is actually T3. Once released from the thyroid gland into the blood, a large amount of T4 is converted to T3 - the active hormone that affects the metabolism of cells throughout our body. The thyroid itself is regulated by another gland located in the brain, called the pituitary. The pituitary is regulated in part by the thyroid by another gland called the hypothalamus. The hypothalamus releases a hormone called thyrotropin releasing hormone (TRH), which sends a signal to the pituitary to release thyroid stimulating hormone (TSH). In turn, TSH sends a signal to the thyroid to release thyroid hormones. If over activity of any of these three glands occurs, an excessive amount of thyroid hormones can be produced, thereby resulting in hyperthyroidism. Similarly, if under activity of any of these glands occurs, a deficiency of thyroid hormones can result, causing hypothyroidism. The hormone chain is represented as Hypothalamus – TRH, Pituitary- TSH, Thyroid - T4 and T3. There is another hormone that is produced by the thyroid called calcitonin. It is a hormone that contributes to the regulation of calcium and helps to lower calcium levels in the blood. Excess calcium in the blood is referred to as hypercalcemia.

Anatomical problems [12] include goiter, endemic goiter, diffuse goiter, multinodular goiter, Lingual thyroid and thyroglossal duct cyst. Tumors include thyroid adenoma, thyroid cancer-Papillary, Follicular, Medullary, Anaplastic and lymphomas and metastasis. Defiency in adults causes Myxedema.

C. *Diagnosis*

The measurement of thyroid hormone levels is often used by doctors as a screening test. If TSH is abnormal, decreased levels of thyroid hormones T4 and T3 may be present. There are two cancer markers for thyroid derived cancers. Thyroglobulin (TG) for well differentiated papillary or follicular adenocarcinoma, and the rare medullary thyroid cancer has calcitonin as the marker. To differentiate between different types of hypothyroidism, a specific test may be used. Thyroid-releasing hormone (TRH) is injected into the body through a vein. This hormone is naturally secreted by the hypothalamus and stimulates the pituitary gland. The pituitary responds by releasing thyroid -stimulating hormone (TSH).

Nodules of the thyroid may or may not be cancer. Medical ultrasonography can help determine their nature because some of the characteristics of benign and malignant nodules differ. The main characteristics of a thyroid nodule on high frequency thyroid ultrasound are as follows[12]

Malignant characteristics	**Benign characteristics**
irregular border	smooth borders
hypoechoic (less echogenic than the surrounding tissue)	hyperechoic
microcalcifications	
taller than wide shape on transverse study	
significant intranodular blood flow by power Doppler	
	comet tail" artifact as sound waves bounce off intranodular colloid

Table 1: benign/malignant characteristics

Ultrasonography is not always able to separate benign from malignant nodules with complete certainty. In suspicious cases, a tissue sample is often obtained by biopsy for microscopic examination. Thyroid scintigraphy, imaging of the thyroid with the aid of radioactive iodine, usually iodine -123, is performed in the nuclear medicine department of a hospital or clinic. Radioiodine collects in the thyroid gland before being excreted in the urine. While in the thyroid the radioactive emissions can be detected by a camera, producing a rough image of the shape (a radiodine scan) and tissue activity (a radioiodine uptake) of the thyroid gland.

A normal radioiodine scan shows even uptake and activity throughout the gland. Irregularity can reflect an abnormally shaped or abnormally located gland, or it can indicate that a portion of the gland is overactive or under active, different from the rest.. In contrast, finding that a substantial section of the thyroid is inactive ("cold") may indicate an area of non-functioning tissue such as thyroid cancer.

The amount of radioactivity can be counted as an indicator of the metabolic activity of the gland. A normal quantitation of radioiodine uptake demonstrates that about 8 to 35% of the administered dose can be detected in the thyroid 24 hours later. Over activity or under activity of the gland as may occur with hypothyroidism or hyperthyroidism is usually reflected in decreased or increased radioiodine uptake. Different patterns may occur with different causes of hypo- or hyperthyroidism.

Published By:
Blue Eyes Intelligence Engineering
and Sciences Publication (BEIESP)

A medical biopsy refers to the obtaining of a tissue sample for examination under the microscope or other testing, usually to distinguish cancer from noncancerous conditions. Thyroid tissue may be obtained for biopsy by fine needle aspiration or by surgery.. The accuracy of the diagnosis depends on obtaining tissue from all of the suspicious areas of an abnormal thyroid gland.

Thyroid disease in children and in autism has many overlapping signs and symptoms. These include but not limited to Feeding problems, Prolonged jaundice, Poor muscletone, Gastrointestinal abnormalities Constipation, Sleep disturbances, Developmental delays, Trouble holding up head, Protrusion of belly Hyperactivity, Lethargy, Lack of play and interaction with others, Dry skin, Poor Hair Growth/Bald spots, Pale complexion, Frequent infections, Cold intolerance, Cold extremities, Weight gain, Difficulty gaining weight Allergies ,Bed wetting, Poor bone development, Fear, Anxiety depression, decreased ability to concentrate, Speech delay, Fading of the personality's color and vivacity, Progressive loss of interest and initiative and iodine deficiency .

III. REVIEW ON THYROID DISORDERS

Preeti Aggarwal et al[15] proposed an automatic segmentation method and two tools: Analyze 10.0 and Mazda for segmentation of thyroid US images.They provides a summary of all the results obtained either by automatic tools as well as by applying specific algorithm (automatic) segmentation on both lung CT as well as on thyroid US .

Nikita Singh et al. [16] have proposed classification using SVM, KNN and Bayesian and also provide information about segmentation and classification methods that are very important for medical image processing. They provide features of malignant nodules and done a comparative study. The results shows that SVM gives much better accuracy than KNN and Bayesian

Eystratios G. et al.[17] have proposed a computer-aided diagnosis (CAD) system prototype, named TND (Thyroid Nodule Detector), for the detection of nodular tissue in ultrasound (US) thyroid images and videos acquired during thyroid US examinations.

Eleonora Horvath et al. [18] have proposed a study using the TIRADS (Thyroid Imaging Reporting and Data System) and The following categories were established:

- TIRADS 1: normal thyroid gland.
- TIRADS 2: benign conditions (0% malignancy).
- TIRADS 3: probably benign nodules (_5% malignancy).
- TIRADS 4: suspicious nodules (5–80% malignancy rate). A subdivision into 4a (malignancy between 5 and 10%) and 4b (malignancy between 10 and 80%) was optional.
- TIRADS 5: probably malignant nodules (malignancy _80%).
- TIRADS 6: category included biopsy proven malignant nodules.

Yutaka Hatakeyama et al. [19] have proposed an algorithm for the size of the thyroid gland in ultrasonography (US) images on the basis of the position of the neighboring regions in order to objectively evaluate target organs for medical screening and secondary use. The proposed algorithm first extracts the target image, with the short-axis view of the thyroid gland and setting information on the scale. Second, it calculates the edge of the carotid region and air passage that are near the target organ. Finally, the length is measured on the basis of these edges.

Mary C. Frates et al. [20] have focus on which nodules should be subjected to US-guided fine needle aspiration and which thyroid nodules need not be subjected to fine-needle aspiration. They provide US features associated with thyroid cancer. Different advanced techniques in image classification like Artificial Neural Networks (ANN), Support Vector Machines (SVM), Fuzzy measures, Genetic Algorithms (GA), Fuzzy support Vector Machines (FSVM) and Genetic Algorithms with Neural Networks are being developed for image classification. Artificial neural networks can handle non-convex decisions. The use of textural features in ANN helps to resolve misclassification. SVM was found competitive with the best available machine learning algorithms in classifying high-dimensional data sets. Fuzzy measures show the detection of textures by analyzing the image by stochastic properties M.Seetha et al. [21] have proposed Fuzzy support vector machines (FSVM) to overcome the n-class problem in Support Vector Machines.

Won-Jin Moon et al. [22] have evaluate the diagnostic accuracy of ultrasonographic (US) criteria for the depiction of benign and malignant thyroid nodules by using tissue diagnosis as the reference standard. They concluded that Shape, margin, echogenicity, and presence of calcification are helpful criteria for the discrimination of malignant from benign nodules The diagnostic accuracy of US criteria dependent on tumor size.

Rajendra Acharya et al. [23] had presented a Computer Aided Diagnosis (CAD) based technique for automatic classification of benign and malignant thyroid lesions in 3D contrast-enhanced ultrasound images. Discrete Wavelet Transform (DWT) and texture based features were extracted from the thyroid images. The resulting feature vectors were used to train and test three different classifiers: K-Nearest Neighbor (K-NN), Probabilistic Neural Network (PNN), and Decision Tree (DeTr) using tenfold cross validation technique. The results are shown in table.

Skrgio Okida et al. [24] had presented the SADNT System to Support the Diagnosis of Thyroid Nodules (TNs). TNs are common clinical problems, involving a great number of diseases with different biological behaviors, from a goiter to a cancer. The SADNT is an expert system (ES) integrated to a database, that uses production rules, certainty factors (CFs) and qualitative reasoning for the computational representation of knowledge. The SADNT integrates information referring to the patient's clinical data (history and physical examination) and the complementary exams (ultrasound, laboratory tests, cytology and thyroid scan) aiming to support the clinician in the diagnosis of TNs. This system is composed by two ES: an ES that is based on clinical data which supplies the initial diagnosis in terms of the chance of the nodule to be malign; a second ES integrates the results of the complementary exams to the diagnostic provided by the first ES, to give a final diagnosis. The SADNT was evaluated by the expert of the domain and the results of the simulations met the expectations.

Nodular thyroid disease is a frequent occurrence in clinical practice and it is associated with increased risk of thyroid cancer and hyperfunction. D.E.

Published By:
Blue Eyes Intelligence Engineering
and Sciences Publication (BEIESP)

Maroulis et al. [25] have proposed a novel method for computer-aided detection of thyroid nodules in ultrasound (US) images. The proposed method is based on a level-set image segmentation approach that takes into account the inhomogeneity of the US images. This novel method was experimentally evaluated using US images acquired from 35 patients. The results show that the proposed method achieves more accurate delineation of the thyroid nodules in the US images and faster convergence than other relevant methods.

Konstantinos K. Delibasis et al. [26] have proposed the utilization of a computer-aided diagnosis system based on a supervised classification algorithm from the artificial immune systems to assist the task of thyroid malignancy diagnosis. The core of the proposed algorithm is the so-called BoxCells, which are defined as parallelepipeds in the feature space. Properly defined operators act on the BoxCells in order to convert them into individual, elementary classifiers. The proposed algorithm is applied on FNA data from 2016 subjects with verified diagnosis and has exhibited average specificity higher than 99%, 90% sensitivity, and 98.5% accuracy.

Elpiniki I. Papageorgiou et al. [27] have prposed a new methodology using the softcomputing technique of FCM's, accompanied with datamining and knowledge extraction techniques. The knowledge extraction techniques with FCM based decision support system develop a method namely FCM-TDM. FCM-TDM provides 89.80% accuracy for thyroid diseases.

Thyroid nodules are solid or cystic lumps formed in the thyroid gland and may be caused by a variety of thyroid disorders. Michalis A. Savelonas et al. [28] had presented a novel active contour model for precise delineation of thyroid nodules of various shapes according to their echogenicity and texture, as displayed in ultrasoundd (US) images. The proposed model, named joint echogenicity–texture (JET), is based on a modified Mumford–Shah functional that, in addition to regional image intensity, incorporates statistical texture information encoded by feature distributions.The JET model requires only a rough region of interest within the thyroid gland as input and automatically proceeds with precise delineation of the nodules, revealing their shape and size. The performance of the JET model was validated on a range of US images displaying hypoechoic and isoechoic nodules of various shapes. The results shows that the JET model provides precise delineations of thyroid nodules as compared to "ground truth" delineations obtained by experts and copes with the limitations of the previous thyroid US delineation approaches as it is capable of delineating thyroid nodules regardless of their echogenicity or shape.

A fine needle aspiration (FNA) biopsy is the standard procedure of choice for differentiating between benign and malignant thyroid nodules. FNA is invasive, costly and uncomfortable for patients. Jieming Ma et al. [29] have presented a non-invasive and automatic approach for differentiating benign and malignant thyroid nodules with ultrasound elastography based on support vector machines (SVM) with biased penalties.They used the elastography data of 98 thyroid nodules (16 malignant and 82 benign) from 92 subjects previously acquired with a clinical ultrasound machine, Hitachi Hi Vision 5500. Also they conducted the leave-one-out cross-validation (LOOCV) in evaluating the performance of their classification method. Their goal was to obtain the maximum geometric mean (MGM) of sensitivity and specificity. The results show that the method was able to get MGM of 90.1% with the sensitivity of 93.8% and the specificity of 86.6%.

D.Selvathi et al. [30] have developed an automatic system that classifies the thyroid images and segments the thyroid gland using machine learning algorithms. The classifiers such as SVM, ELM are used. The features such as mean, variance, Coefficient of Local Variation Feature, Histogram Feature, NMSID Feature, and Homogeneity are extracted and these features are used to train the classifiers such as ELM and SVM. The results are compared with the ground truth images obtained from the radiologist and the performance measure such as accuracy is evaluated. It is observed that the segmentation using ELM is better than SVM classifier.

Chuan-Yu Chang et al. [1] have presented a progressive learning vector quantization neural network (PLVQNN) combined with a reprocessing procedure is proposed for automatic thyroid segmentation and volume estimation using computerized tomography (CT) images. The preprocessing procedure is used to extract the region of interest (ROI) of thyroid glands and exclude non-thyroid glands based on thyroid anatomy. The PLVQNN contains several learning vector quantization neural networks (LVQNNs), each responsible for segmenting one slice of a thyroid CT image. The training of the PLVQNN is conducted starting from the LVQNN of most reliable (middle) slices, where the thyroid has the largest region. The training then propagates upwards and downwards to adjacent LVQNNs using the results of the middle slice as the initialization values and constraints. Experimental results show that the proposed method can effectively segment thyroid glands and estimate thyroid volume.

Jianrui Ding et al. [2] have proposed a new effective, accurate, and quantitative metric using computer aided diagnosis (CAD) techniques . The statistical features and texture features are extracted from the lesion region on the elastogram. The important and reliable features are selected by using Minimum-Redundancy-Maximum-Relevance (mRMR) algorithm. The selected features were input to the SVM to classify the thyroid nodules. The experiment results confirm that the method is more accurate and robust than color score and strain ratio.

Chuan-Yu Chang et al. [3] have proposed the radial basis function neural network to classify blocks of the thyroid gland. The integral region is acquired by applying a specific-region-growing method to potential points of interest. The parameters for evaluating the thyroid volume are estimated using a particle swarm optimization algorithm. The experiment results show that the proposed method can be used to segment the thyroid gland region and to estimate thyroid volume directly from US images

Chuan-Yu Chang et al. [4] had presented five support vector machines (SVM) to select the significant textural features and to classify the nodular lesions of thyroid. Experimental results showed the proposed method classifies the thyroid nodules correctly and efficiently. The comparison results demonstrated that the capability of feature selection of the proposed method was similar to the sequential floating forward selection (SFFS) method. However, the proposed method is faster than the SFFS method.

Published By:
Blue Eyes Intelligence Engineering
and Sciences Publication (BEIESP)

Deepika Koundal1 et al. [5] have provided a summary of existing automatic tools available to formulate the disease diagnosis part easier as well efficient. Different performance evaluation metrics are studied, and the future developments and trends are also investigated.

Singh1 and Mrs Alka Jindal [6] had uses the groups Benign (non-cancerous) and Malignant (cancerous) Thyroid Nodules images . The texture feature method like GLCM are very useful for classifying texture of images and these features are used to train the classifiers such as SVM, KNN and Bayesian. The experimental result shows the performance of the classifiers and shows the best predictive value and positively identify the percentage of the non-cancerous or cancerous people and shows the best performance accuracy using the SVM classifier as compare to the KNN and Bayesian classifier. Use the segmentation based algorithm localized based active contour (region based) method is basically to segment the local area of the images and to segment the nodule which is give the information of which type nodule exist benign and malignant. The proper procedure of segmentation algorithm the thyroid benign image are segmented with Quantitative measurement of classification accuracy is calculated in term of true positive (TP), true negative (TN), false positive (FP), false negative (FN) with respect to the ground truth.

Edgar Gabriel et al. [7] had presented their experiences with two parallel versions of a code used for texture-based segmentation of thyroid FNAC images, a critical first step in realizing a fully automated CAD solution. An MPI version of the code is developed to exploit distributed memory compute resources such as PC clusters.

M. Savelonas et al. [8] have proposed a novel active contour model named Variable Background Active Contour model is proposed and applied for the detection of thyroid nodules in ultrasound images. The new model offers edge independency, no need for smoothing, ability for topological changes and it is more accurate when compared to the Active Contour Without Edges model. improved accuracy is achieved by introducing as background a limited image subset which appropriately changes shape to reduce the effects of background inhomogeneity.

Nasrul Humaimi Mahmood and Akmal [9] had presented a simple guide of determine the thyroid lobes in the thyroid ultrasound image using a MATLAB. The image undergoes the contrast enhancement to suppress speckle. The enhancement image is used for further processing of segmentation the thyroid region by local region-based active contour. The thyroid region is segmented into two parts, which are right and left with the active contour method separately. This is accordingly to the thyroid have two lobes; right lobe and left lobe. Thyroid ultrasound image of transverse view is used in this study. Therefore, the measurements only involve the width, depth and area of the thyroid region. The result of thyroid measurement is successfully calculated in pixel unit. The measurement is converted in centimetre (cm) unit. The proposed method is benefited to enhance the image and segmentation the thyroid lobe. It shows that from five samples, different people have different size of thyroid, especially in measurement of the width, depth and area.

Dimitris E. Maroulis [10] had presented a computer-aided approach for nodule delineation in thyroid ultrasound (US) images. The developed algorithm is based on a novel active contour model, named variable background active contour (VBAC), and incorporates the advantages of the level set region-based active contour without edges (ACWE) model, offering noise robustness and the ability to delineate multiple nodules. Unlike the classic active contour models that are sensitive in the presence of intensity inhomogeneities, the proposed VBACmodel considers information of variable background regions. VBAC has been evaluated on synthetic images, as well as on real thyroid US images. From the quantification of the results, two major impacts have been derived- higher average accuracy in the delineation of hypoechoic thyroid nodules, which exceeds 91% and faster convergence when compared with the ACWE model.

IV. REVIEWED RESULTS

The segmentation accuracy of different researches are shown below. Depending on the thyroid diseases the accuracy is varied.

reference	Segmentation method	Accuracy %
1	PLVQNN	98.34
3	RBFNN	96.54
6	SVM	84.62
20	FCM-TDM	89.8
23	KNN	98.9
23	PNN	97.8
23	Decision tree	96.9
29	SVM with biased penalities	90.1
30	ELM	93.56

Table 2: comparison of thyroid segmentation accuracies of different researches

A graphical representation is also shown below.

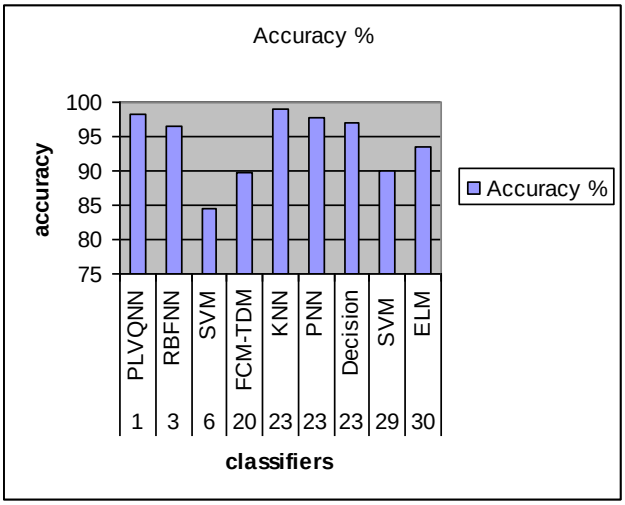

Fig 2: comparison of thyroid segmentation accuracies of different researches

V. CONCLUSION

Different researchers have been developed various techniques to process thyroid medical images. Such techniques helps the radiologists and doctors to efficiently diagnosing the nodules in thyroid images and lead the reduction of false diagnosis thyroid diseases.

Published By:
Blue Eyes Intelligence Engineering
and Sciences Publication (BEIESP)

Different classifiers improve the performance of classifying thyroid nodules as cancer/non- cancerous. This review work provides knowledge about thyroid, thyroid diseases, thyroid diagnosis and also gives a summary of thyroid segmentation accuracies of different researches in various thyroid diseases. We think that this work will direct the future researchers to develop the better methods for the diagnosis of thyroid diseases.

REFERENCES

[1] Chuan-Yu Changet al. "A Neural Network for Thyroid Segmentation and Volume Estimation in CT Images", November 2011 IEEE COMPUTATIONAL INTELLIGENCE MAGAZINE, pp 43-55

[2] Jianrui Ding et al. "A novel quantitative measurement for thyroid cancer detection based on elastography", 4th International Congress on Image and Signal Processing 2011

[3] Chuan-Yu Chang et al. "Thyroid Segmentation and Volume Estimation in Ultrasound Images", IEEE TRANSACTIONS ON BIOMEDICAL ENGINEERING, VOL. 57, NO. 6, JUNE 2010

[4] Chuan-Yu Chang et al. "Classification of the Thyroid Nodules Using Support Vector Machines", International Joint Conference on Neural Networks (IJCNN) 2008

[5] Deepika Koundal1 et al.," Computer-Aided Diagnosis of Thyroid Nodule: A Review",International Journal of Computer Science & Engineering Survey (IJCSES) Vol.3, No.4, August 2012

[6] Singh1 and Mrs Alka Jindal," A segmentation method and classification of diagnosis for thyroid nodules", . IOSR Journal of Computer Engineering (IOSRJCE) ISSN : 2278-0661 Volume 1, Issue 6 , PP 22-27,2012

[7] Edgar Gabriel et al. "Towards high performance cell segmentation in multispectral fine needle aspiration cytology of thyroid lesions", computer methods and programs in biomedicine, pp 1-10

[8] M. Savelonas et al. "Variable Background Active Contour Model for Automatic Detection of Thyroid Nodules in Ultrasound Images", Dept. of Informatics and Telecommunication

[9] Nasrul Humaimi Mahmood and Akmal," Segmentation and Area Measurement for Thyroid Ultrasound Image", International Journal of Scientific & Engineering Research Volume 2, Issue 12, December 2011

[10] Dimitris E. Maroulis," Variable Background Active Contour Model for Computer-Aided Delineation of Nodules in Thyroid Ultrasound Images", IEEE TRANSACTIONS ON INFORMATION TECHNOLOGY IN BIOMEDICINE, VOL. 11, NO. 5, SEPTEMBER 2007

[11] http;//www.nlm.nih.gov/medlinep/us/ency/article/000371.htm

[12] http://www.wikipedia.com

[13] http://thyroid.about.com/library/weekly/qathyroid 101-e.htm

[14] http://ww.medicinenet.com/script/main/at.asp

[15.] Preeti Aggarwal et al. "Role of Segmentation in Medical Imaging: A Comparative Study" International Journal of Computer Applications (0975 – 8887) Volume 29– No.1, September 2011

[16] Nikita Singh et al. " A Segmentation Method and Comparison of Classification Methods for Thyroid Ultrasound Images" International Journal of Computer Applications (0975 – 8887) Volume 50 – No.11, July 2012

[17] Eystratios G.et al." TND: A Thyroid Nodule Detection System for Analysis of Ultrasound Images and Videos" Springer Science+Business Media, LLC 2010

[18] Eleonora Horvath et al." An Ultrasonogram Reporting System for Thyroid Nodules Stratifying Cancer Risk for Clinical Management", J Clin Endocrinol Metab 90: 1748–1751, 2009

[19] Yutaka Hatakeyama et al. "Algorithm for Estimation of Thyroid Gland Size in Ultrasonography Images for Extracting Abnormal Thyroid in Medical Practice" Journal of Advanced Computational Intelligence and Intelligent Informatics Vol.16 No.1, 2012

[20] Mary C. Frates et al. "Management of Thyroid Nodules Detected at US: Society of Radiologists in Ultrasound Consensus Conference Statement" Management of Thyroid Nodules Detected at US Volume 237 , Number 3

[21] M.Seetha et al." ARTIFICIAL NEURAL NETWORKS AND OTHER METHODS OF IMAGE CLASSIFICATION", Journal of Theoretical and Applied Information Technology,2008

[22] Won-Jin Moon et al." Benign and Malignant Thyroid Nodules: US Differentiation—Multicenter Retrospective Study" Radiology: Volume 247: Number 3—June 2008

[23] U Rajendra Acharya et al." Automated Benign & Malignant Thyroid Lesion Characterization and Classification in 3D Contrast-Enhanced Ultrasound"34th Annual International Conference of the IEEE EMBS San Diego, California USA, 28 August - 1 September, 2012

[24] Skrgio Okida et al. "Expert System to Support the Diagnosis of Thyroid Nodules", Proceedings of the 22''' Annual EMBS international Conference, July 23-28,2000, Chicago IL.

[25] D.E. Maroulis et al. "Computer-Aided Thyroid Nodule Detection in Ultrasound Images", Proceedings of the 18th IEEE Symposium on Computer-Based Medical Systems (CBMS'05) 2005 IEEE

[26] Konstantinos K. Delibasis et al." Computer-Aided Diagnosis of Thyroid Malignancy Using an Artificial Immune System Classification Algorithm", IEEE TRANSACTIONS ON INFORMATION TECHNOLOGY IN BIOMEDICINE, VOL. 13, NO. 5, SEPTEMBER 2009

[27] Elpiniki I. Papageorgiou et al." Fuzzy cognitive map based decision support system for thyroid diagnosis management", IEEE International Conference on Fuzzy Systems(FUZZ) 2008.

[28] Michalis A. Savelonas et al" Active Contours Guided by Echogenicity and Texture for Delineation of Thyroid Nodulesin Ultrasound Images", IEEE TRANSACTIONS ON INFORMATION TECHNOLOGY IN BIOMEDICINE, VOL. 13, NO. 4, JULY 2009

[29] Jieming Ma et al. "Differential Diagnosis of Thyroid Nodules with Ultrasound Elastography based on Support Vector Machines" , IEEE International Ultrasonics Symposium Proceedings 2010

[30] D.Selvathi et al. "Thyroid Classification and Segmentation in Ultrasound Images Using Machine Learning Algorithms" Proceedings of International Conference on Signal Processing, Communication, Computing and Networking Technologies (ICSCCN) 2011

Published By:
Blue Eyes Intelligence Engineering and Sciences Publication (BEIESP)